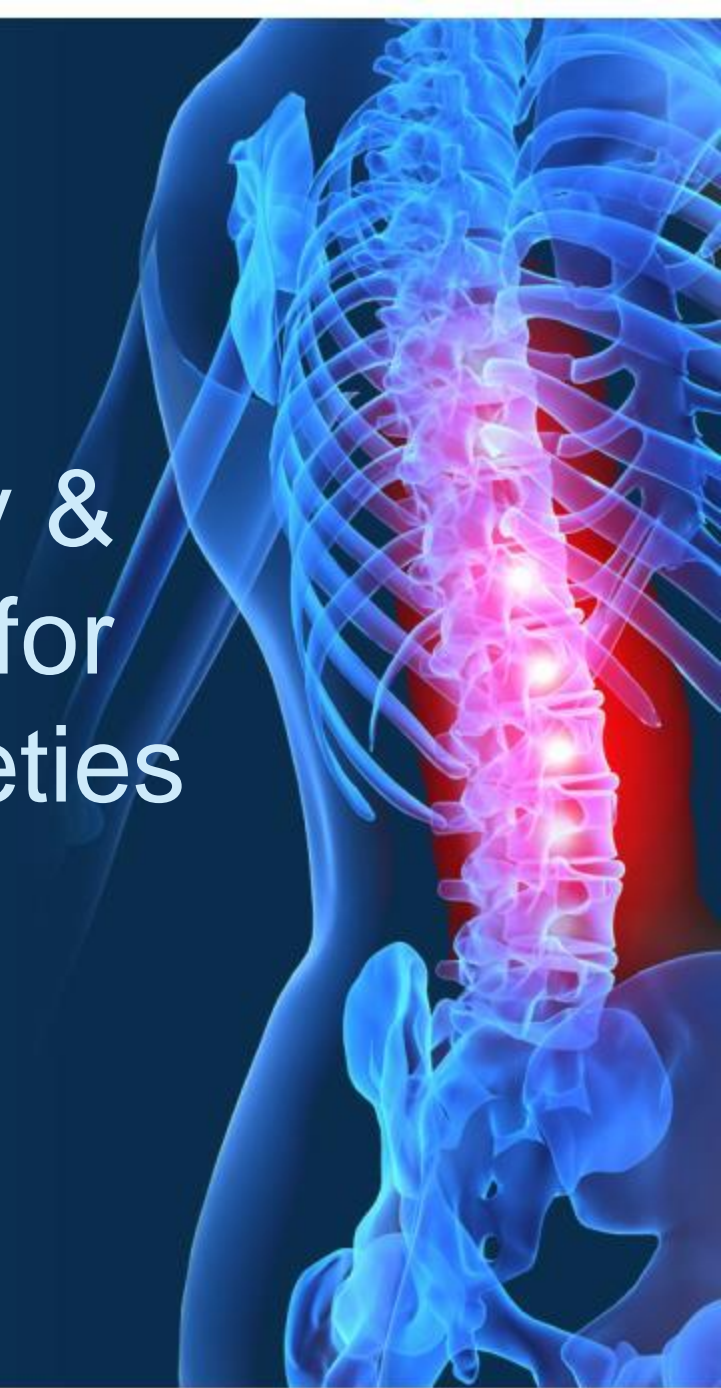
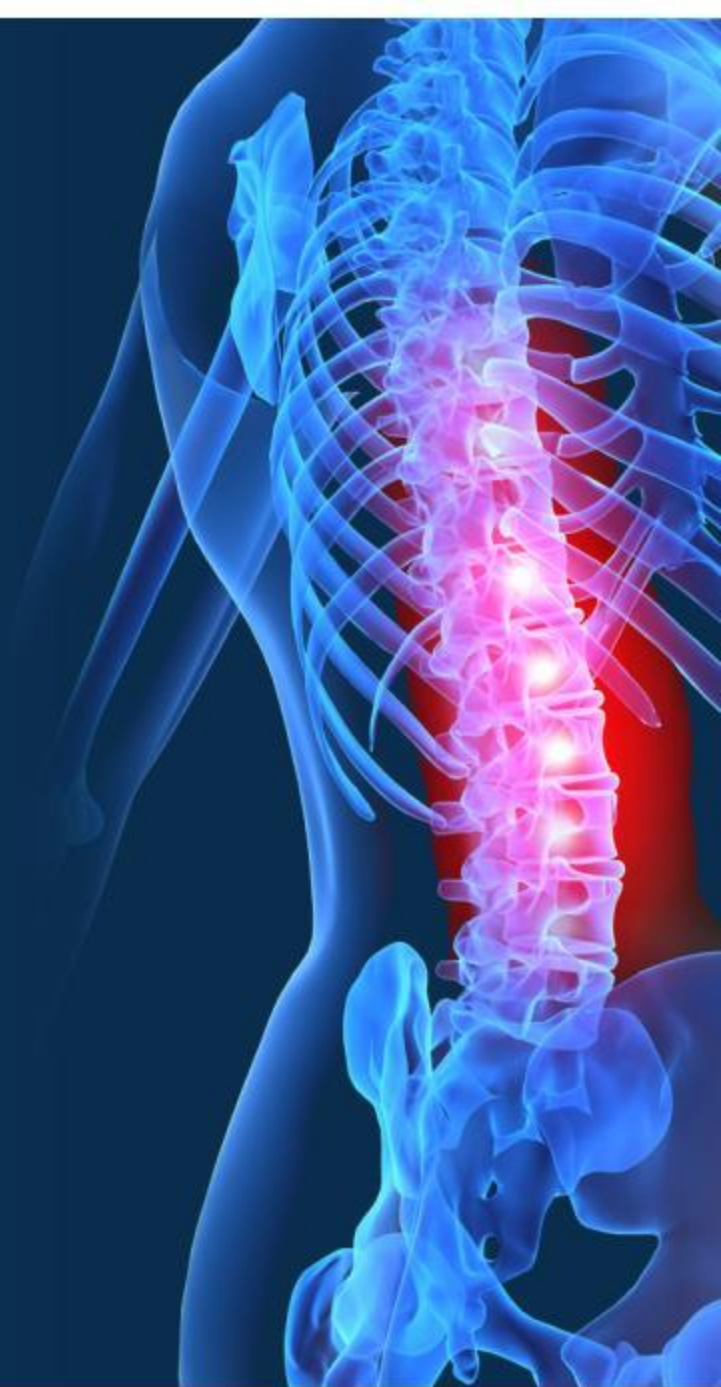

Annual Rheumatology & Therapeutics Review for Organizations & Societies



Update on Inflammatory Myositis



- The following talk includes discussion on “off-label” usage of Campath, Rituximab, Leflunomide, and Anakinra.

Approach to the Patient w/ Myositis

- Overview
- Unique Scenarios
 - Amyopathic Dermatomyositis
 - Cancer and IIM
 - Statin Myopathy; Statin-induced myositis
 - Intersititial Lung Disease
 - Calcinosis
 - Myositis Ossificans
- Diagnosis
 - Clinical (Criteria)
 - Laboratory testing
 - Anti-Synthetase Abs
- Refractory IIM Treatment
 - Standard of Care
 - Leflunomide
 - CyA, Tacrolimus, MMF
 - IVIG, others
- Juvenile JDM outcomes
- Prognosis

Polymyositis - Dermatomyositis

- F:M = 2.5:1
- Acute onset; all ages (bimodal)
- Incidence 2-7 million/year
 - Prevalence: 2003 of polymyositis/dermatomyositis was estimated to be 21.5/100,000 (range: 3-70)
- Weakness (\pm myalgia): Proximal > Distal
- Skeletal muscle: dysphagia, dysphonia
- Sxs: Rash, Raynauds, dyspnea
- **65%** elevated CPK, aldolase
- 50% ANA (+)
- 90% +EMG; 85% + muscle biopsy



Polymyositis Classification

Bohan & Peter

1. Primary idiopathic dermatomyositis (DM)
2. Primary idiopathic polymyositis (PM)
3. Adult PM/DM associated with neoplasia
4. Juvenile Dermatomyositis (JDM)
 - often associated with vasculitis
5. Myositis associated with collagen vascular disease

Proposed Criteria for Myositis

1. Symmetric proximal muscle weakness
 2. Elevated Muscle Enzymes (CPK, aldolase, AST, ALT, LDH)
 3. Myopathic EMG abnormalities
 4. Typical changes on muscle biopsy
 5. Typical rash of dermatomyositis
- PM Dx is Definite w/ 4 criteria and Probable w/ 3 criteria
 - DM Dx Definite w/ rash and 3 criteria and Probable w/ rash and 2 criteria

Myopathy: Historical Considerations

- Age/Sex/Race
- Acute vs. Insidious Onset
- Distribution: Proximal vs. Distal
- Pain?
- Drugs/Pre-existing Conditions
- Trauma
- Neuropathy
- Systemic Features

Myopathies

- Infectious
 - Coxsackie A9, Adenovirus, CMV, HBV, HIV, influenza, Strep., Staph, Clostridial, Toxoplasma, Trichinella, Toxocara, Dengue
- Congenital Neuromuscular Disorders
 - Muscular dystrophies, hereditary myopathies
- Neuropathic/Motor Neuron Disorders
 - Myasthenia gravis, amyotrophic lateral sclerosis
- Endocrine/Metabolic
 - Glycogen storage, mitochondrial myopathies

Drug-Induced Myopathy

Amiodarone

Amphetamines

Chloroquine

Cimetidine

Cocaine

Colchicine

Corticosteroids

Cyclosporine

Danazol

Emetine

Ethanol

Fibrates

Gemcitabine

Heroin

Hydralzaine

Hydroxychloroquine

Hydroxyurea

Levodopa

Nicotinic acid

Pancuronium

Penicillamine

Pentazocine

Phenytoin

Procainamide

Protease inhib.

Rifampin

Statins

Sulfonamides

Tiopronin

Vecruonium

Vincristine

Zidovudine

Antimalarial Neuromyopathy

- Drugs: hydroxychloroquine, chloroquine
- Not dose or duration dependent
- Insidious painless LE/UE weakness
- Clinical myopathy 6.7%; Chemical myopathy 18.8%
 - PI “monitor reflexes and for muscle weakness”
- Bx: classic vacuolar myopathy and EM curvilinear bodies/complex lysosomes
- Rx: improvement within 2 mos of HCQ discontinuation

Statin Myopathy/Myositis

- More common in elderly, those on myopathic Rx
 - ⊗w/ CyA, gemfibrozil, itraconazole, EES, clarithromycin, protease inhibitor
- Onset – 1st 6 mos; Sxs last 1-6 mos on discontinuation
- LFT elevations \leq 3 fold – up to 50%
- Risk of rhabdomyolysis 5-18%
 - Incidence: 3.5 cases /100,000 PY w/ standard-doses
- Renal dysfunction 4%
- Rx: D/c, Lowest dose, d/c con meds, lifestyle change
- 14 reports of Statin related IIM: 10 PM, 14 DM, and 63 cases with necrotizing myopathies (Anti-HMGCR ab)

Statin Induced Autoimmune Myopathy

- Background: Statin use can result in a self limited myopathy. In some patients statin exposure may trigger a chronic immune mediated necrotizing myopathy (IMNM).
- 6% of the 750 patients in the Johns Hopkins Myositis Center cohort with IMNM shown to have 100kD autoantibody against 3 hydroxy 3 methylglutaryl coenzyme reductase (HMGCR)
 - Prox weakness, mean CK 9718, EMG myopathy, necrotizing myositis bx, 92% statin exposure (age >50)
- In vitro, statins increase HMGCR expression in muscle cells
- Statins upregulate HMGCR expression; autoantigen in IMNM
- Regenerating muscle cells express high levels of HMGCR, which may sustain the immune response even after statins are discontinued.

Necrotizing Myopathy

- Necrotizing myopathy is rare (but increasing) entity & may be assoc w/ myositis specific Abs:
 - anti-HMGCR Abs from Statins
 - Anti- PL-12 Abs
 - Anti- PL-17 Abs
 - Signal Recognition Particle Ab

Rhabdomyolysis

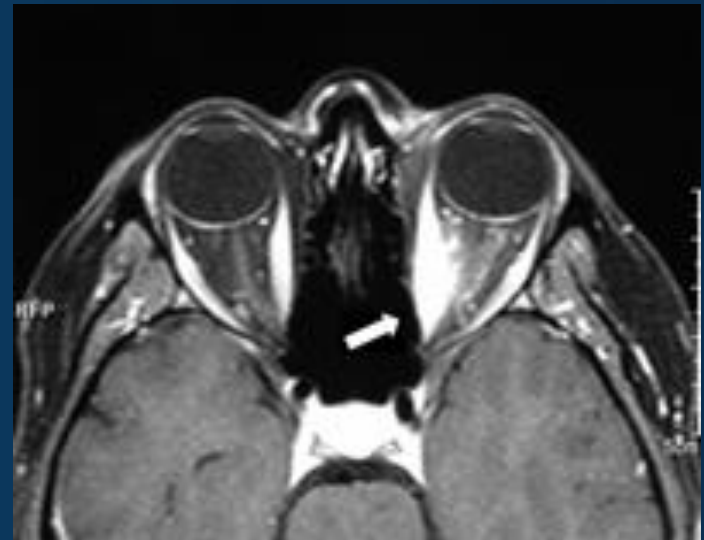- Injury to the sarcolemma of skeletal muscle with systemic release of muscle macromolecules such as CPK, aldolase, actin, myoglobin, etc
- LIFE-THREATENING: from hyperkalemia, metabolic acidosis, ATN from myoglobinuria
- Common causes: EtOH, Cocaine, K⁺ deficiency, infection, **PM/DM**, infection (clostridial, staph, strep), exertion/exercise, cytokines
- Small risk of 0.44 cases per 10,000 person-years.

Focal Myositis

- Considerations
 - PMHx – Diabetes (Diabetic amyotrophy)
 - Trauma, focal damage, compression (S1 Radiculopathy)
 - Infection (Trichinosis, Trichinella, cysticercosis, TB)
 - Systemic: FMF
- Diagnostic methods
 - Ultrasound
 - MRI
 - Needle Bx

Orbital Myositis

- Considerations
 - Myositis etiologies + Infection
 - Idiopathic
 - **Orbital pseudotumor**
 - Still's disease
 - Wegeners
 - SLE
 - Sarcoidosis
 - IBD
 - IgG4 related systemic diseases



CMAJ January 16, 2007 vol. 176 no. 2

Inclusion Body Myositis (IBM)

- Bimodal age distribution, may be hereditary
- Slow onset, progressive (asymmetric) weakness
- Painless, distal and proximal (asymmetric) weakness, dysphagia
- Normal or mildly elevated CPK (usually below 2,000 IU/ml)
- Poor response to corticosteroids
- Dx: light microscopy normal or show CD8+ lymphs. Tubulofilamentous inclusion bodies on EM
- Role for amyloid? sIBM Ab?
- New Rx: Alemtuzumab (Campath) in inclusion body myositis

Differentiating PM, DM, IBM

	DM	PM	IBM
Onset	Early	Early	Late
M/F	F>M	F>M	M>F
Weakness	proximal	proximal	distal
Typical pathology	Perifascicul atrophy	Invasion of indiv fibers	Vacuoles
Steroid Sensitivity	Yes	Yes	No

Nonmyopathic Considerations

- Fibromyalgia – “Total body toothache”
- Polymyalgia Rheumatica
 - Caucasians, > 60 yrs, M=F, ESR > 100, normal strength, no synovitis
- SLE
- Adult Still's Disease
- Vasculitis

Presentation of PM/DM

Presentation	Frequency (%)
Painless proximal weakness (over 3-6 mos)	55%
Acute/subacute proximal pain and weakness (wks-2 mos)	30%
Insidious proximal/distal weakness (< 10 yrs)	10%
Proximal myalgia alone	5%
Dermatomyositis sine myositis	<1%

Amyopathic Dermatomyositis

- AKA Dermatomyositis sine myositis, Clinically amyopathic dermatomyositis (CADM)
- ILD associated w/ poor outcomes in PM/DM
 - CADM-ILD rapidly progressive ILD & 6-mo survival 40.8%
 - DM-ILD also a progressive pattern & 5-year survival 54%
 - PM-ILD more chronic: 5 & 10-yr survival 72.4% and 60.3%
- “hypomyopathic DM” + DM skin dz x 6 mo but no weakness but have evidence of muscle inflammation
- 291 adult-onset CADM, 73%F, 13% developed weakness 15mos-6yrs after. < 15% develop ILD or neoplasia.
 - 63% ANA+ (3.5% +anti-synthetase Abs)
- Anti-CADM 140 Abs; RP-ILD, severe skin dz

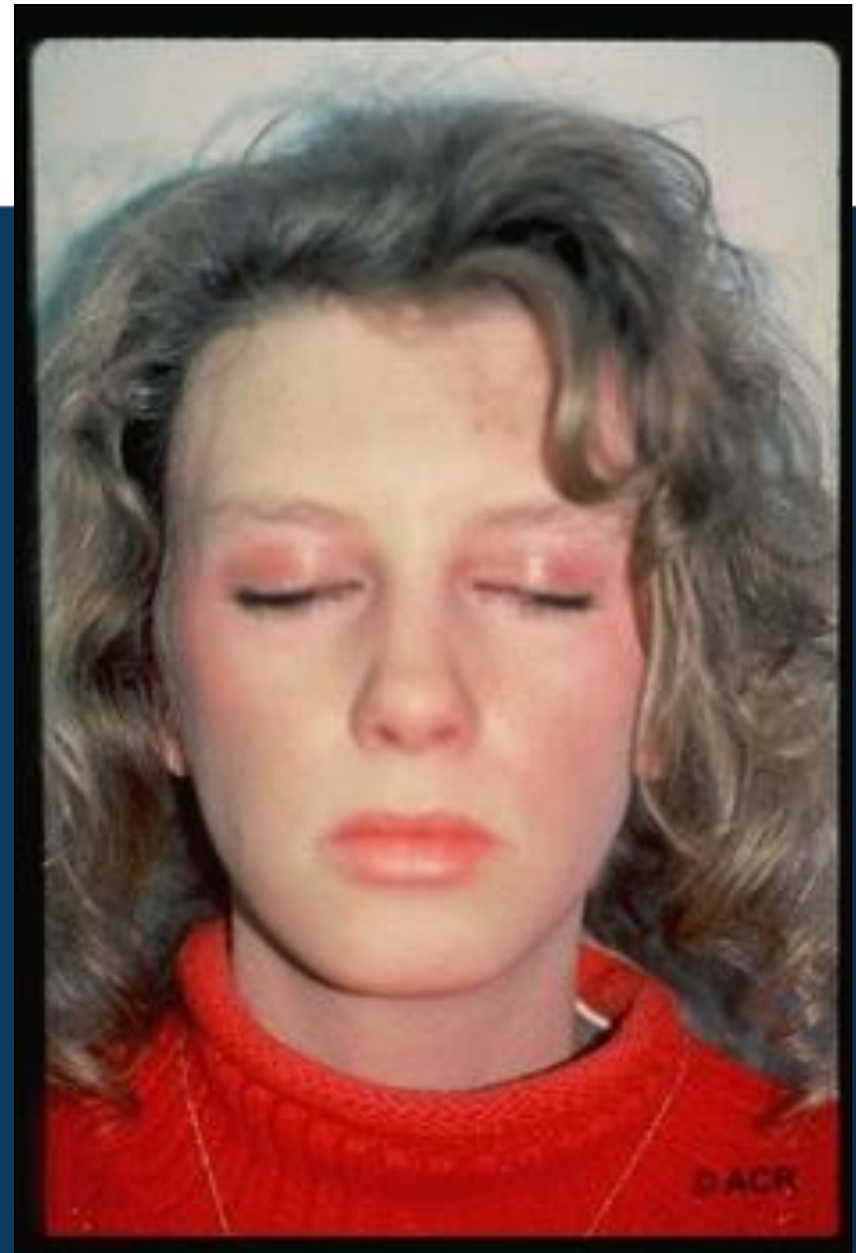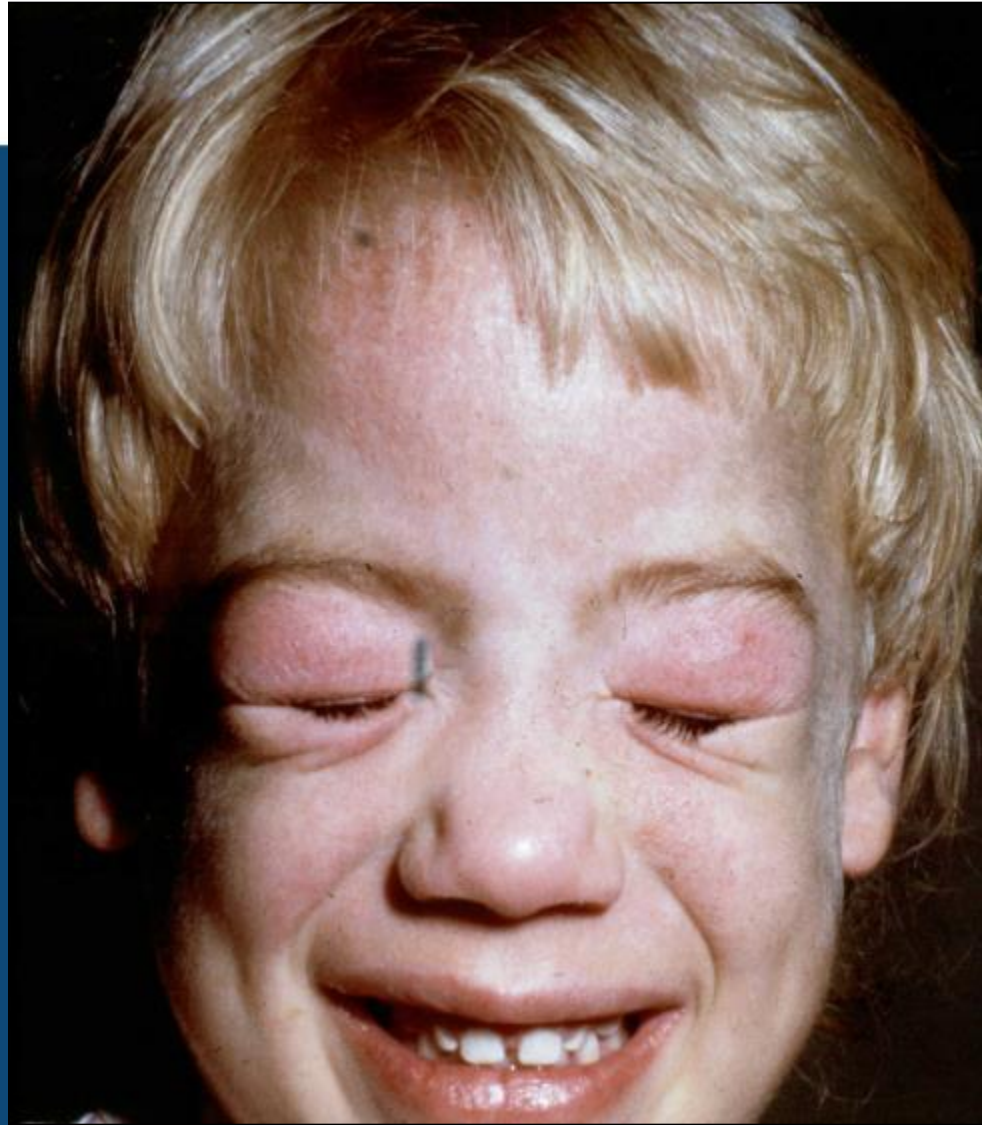
Amyopathic Dermatomyositis

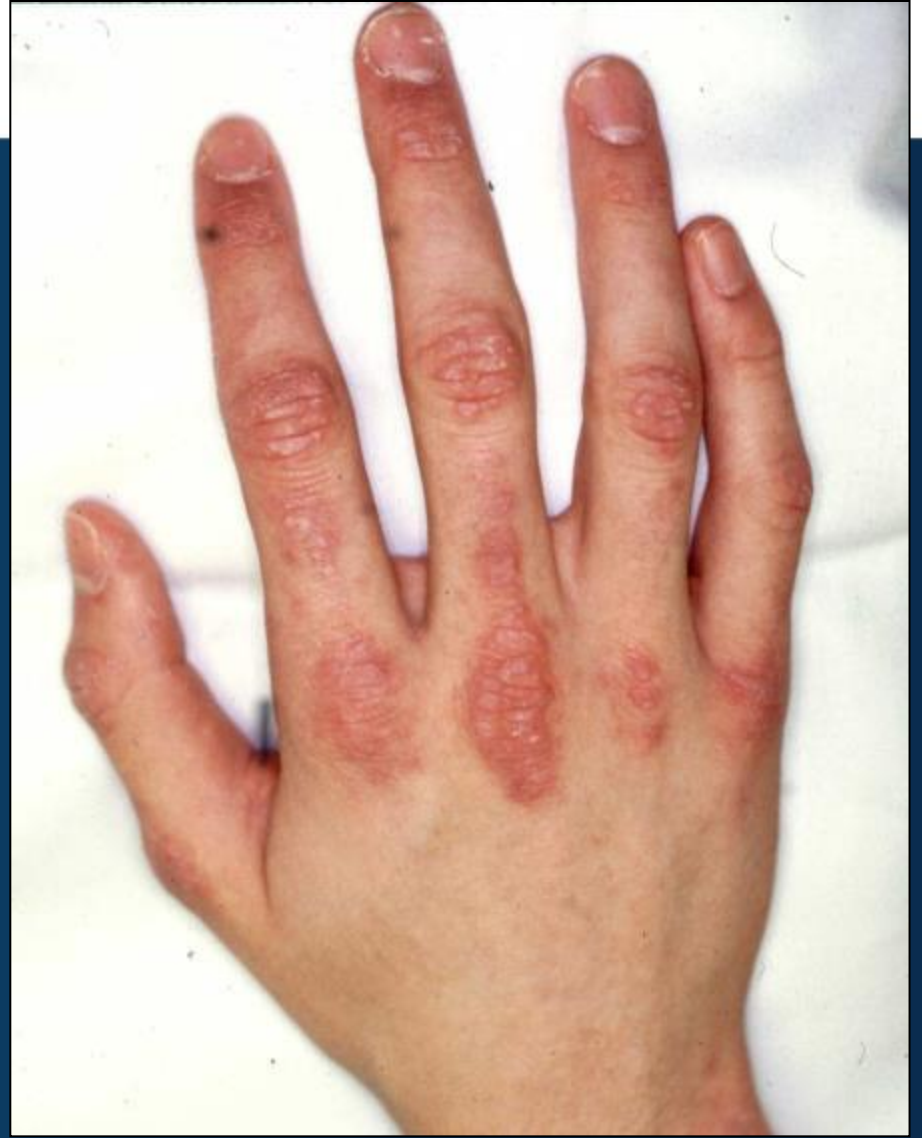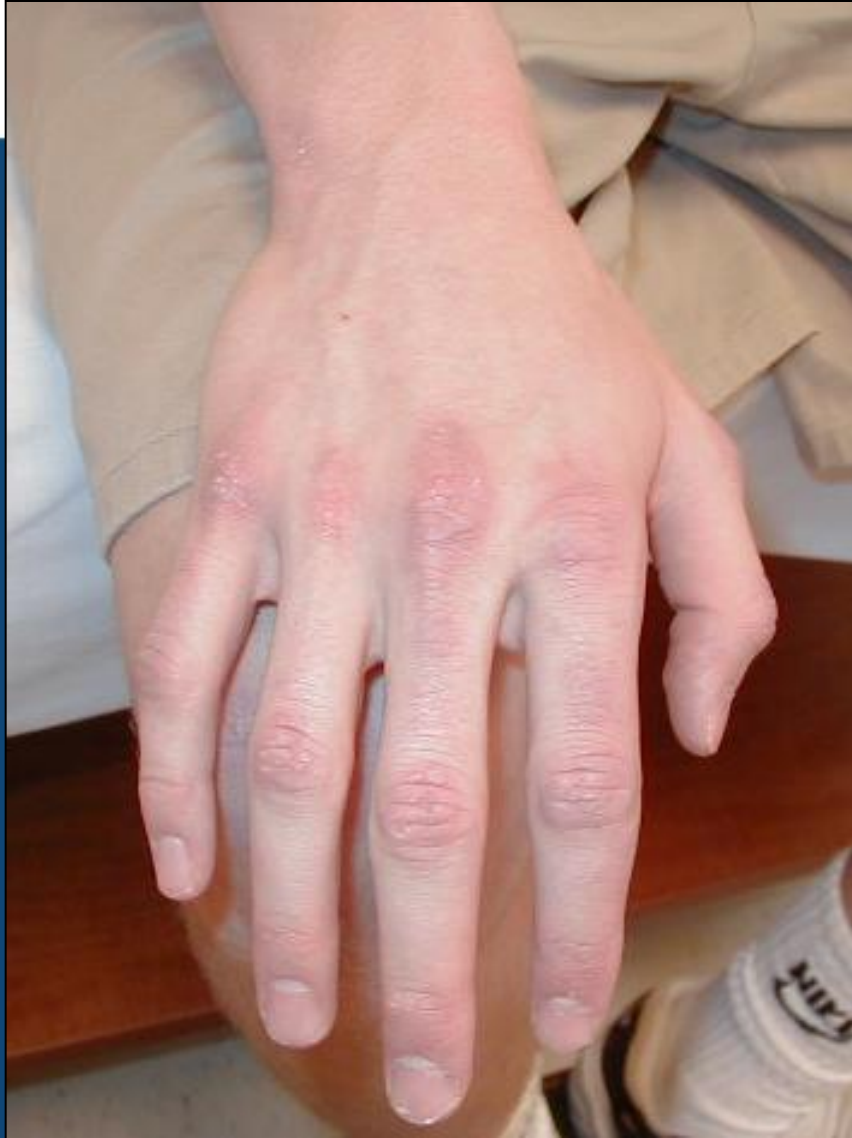- AKA Dermatomyositis sine myositis, Clinically amyopathic dermatomyositis (CADM)
- ILD associated w/ poor outcomes in PM/DM
 - CADM-ILD rapidly progressive ILD & 6-mo survival 40.8%
 - DM-ILD also a progressive pattern & 5-year survival 54%
- 291 adult-onset CADM:
 - 73%F, 13% developed weakness 15mos-6yrs after.
 - < 15% develop ILD or neoplasia.
 - 63% ANA + (3.5% +anti-synthetase Abs)
- Anti-CADM 140 Abs; RP-ILD, severe skin dz

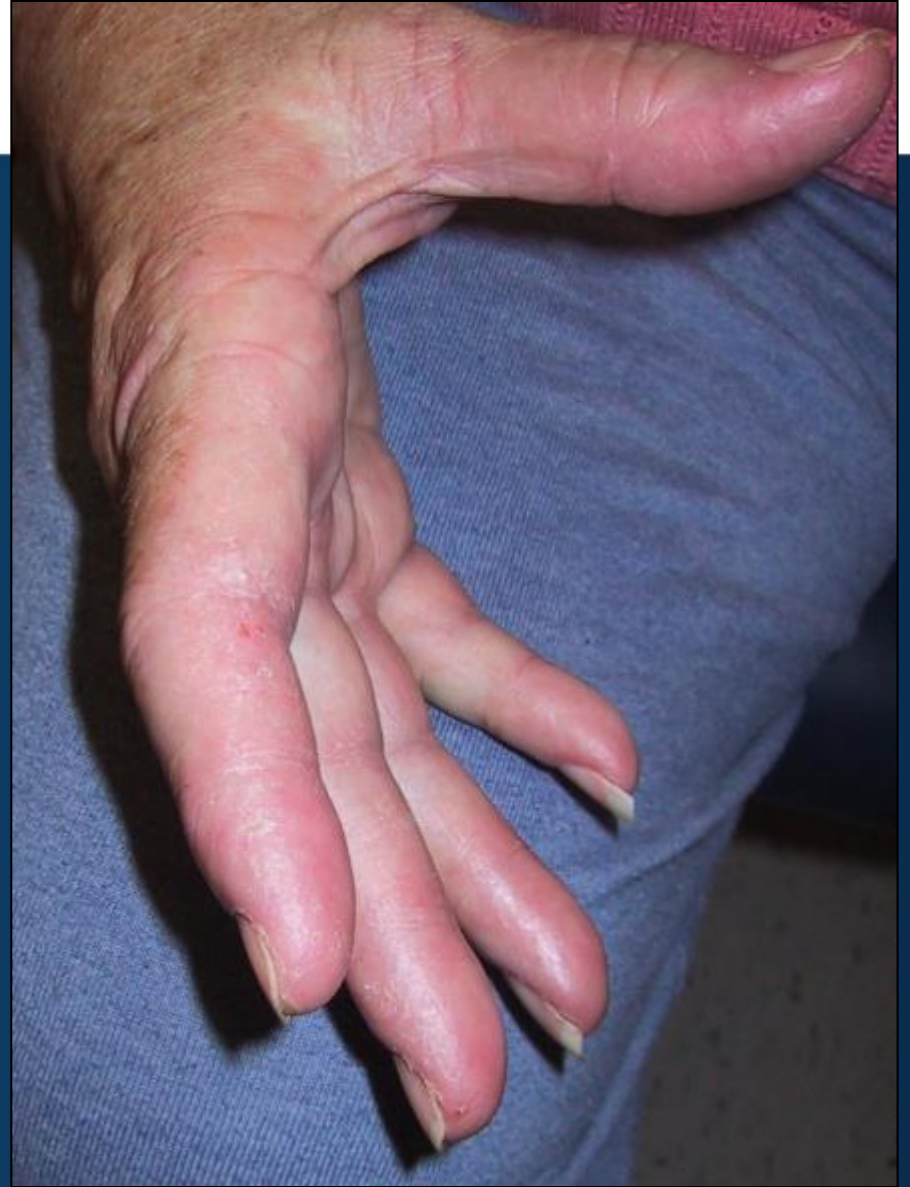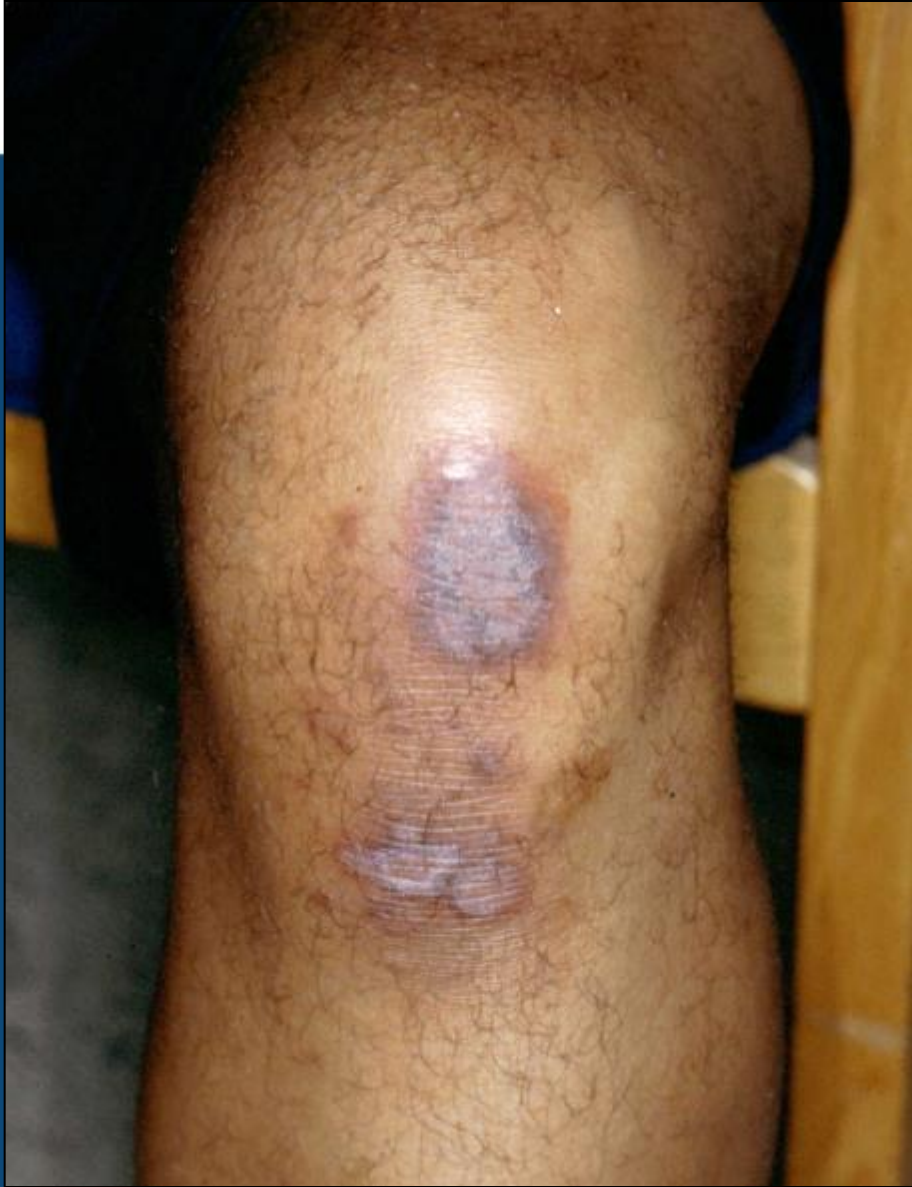Dermatomyositis

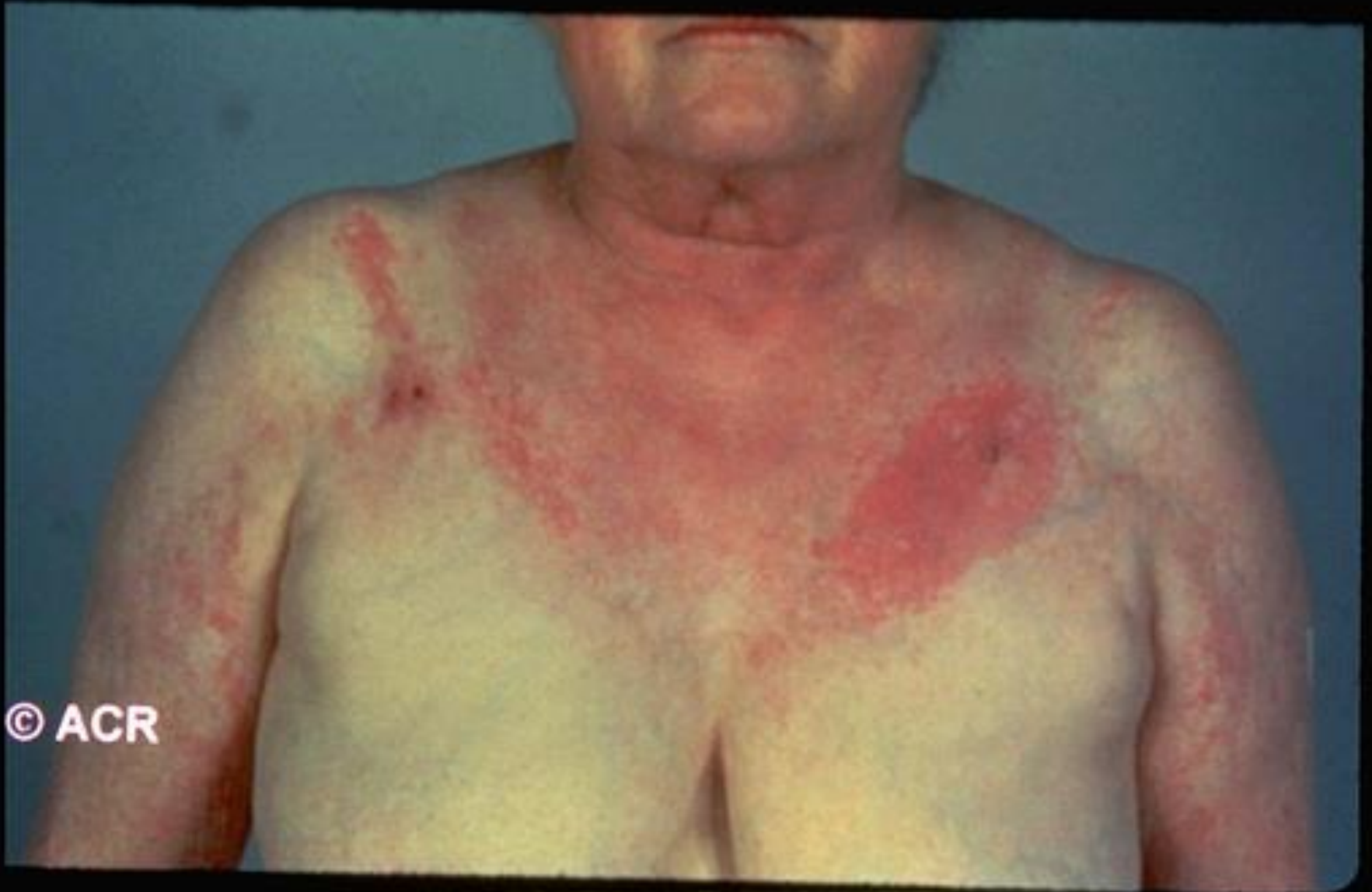6 Skin Features

1. Heliotrope Rash: over eyelids
 - Seldom seen in adults
2. Gottrons Papules (60-80%): MCPs, PIPs, MTPs, knees, elbows
3. V-Neck Rash (Shawl sign): violaceous erythema ant. chest w/ telangiectasias
4. Periungual erythema, digital ulcerations
5. Calcinosis
6. Mechanics hands



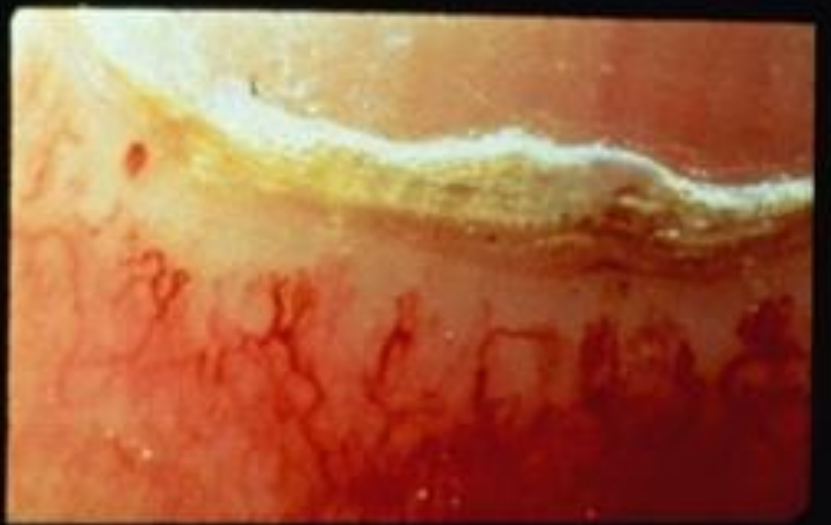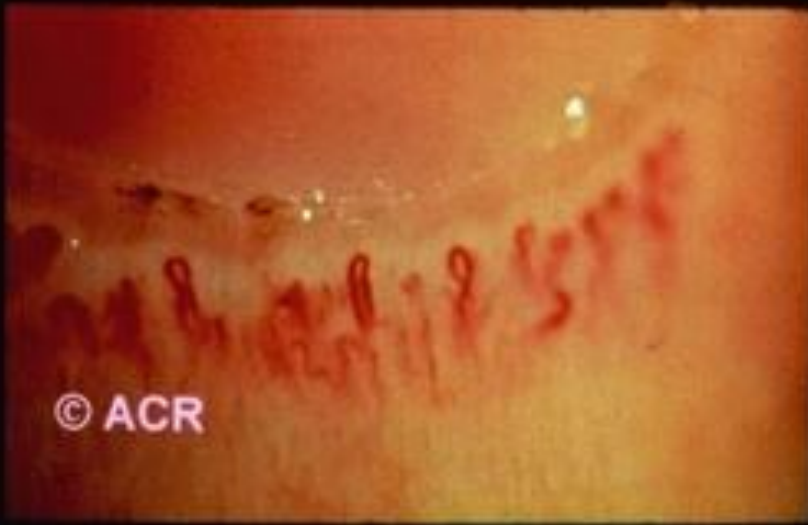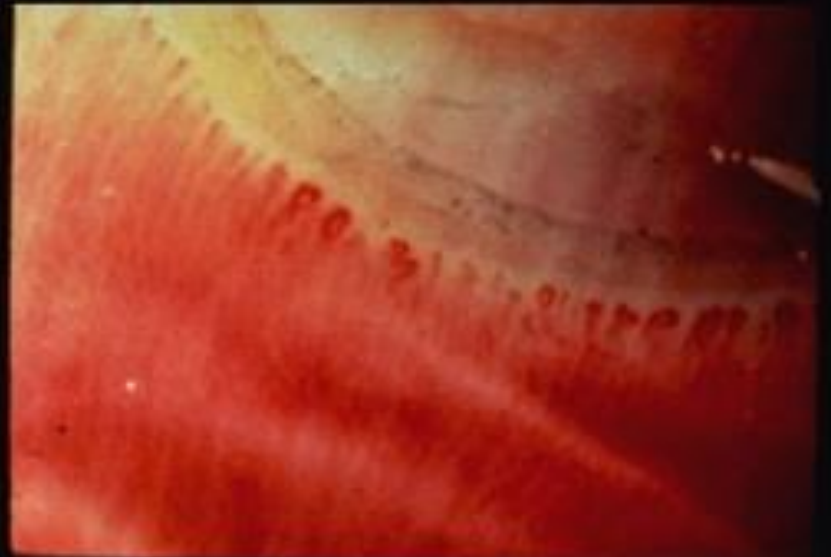
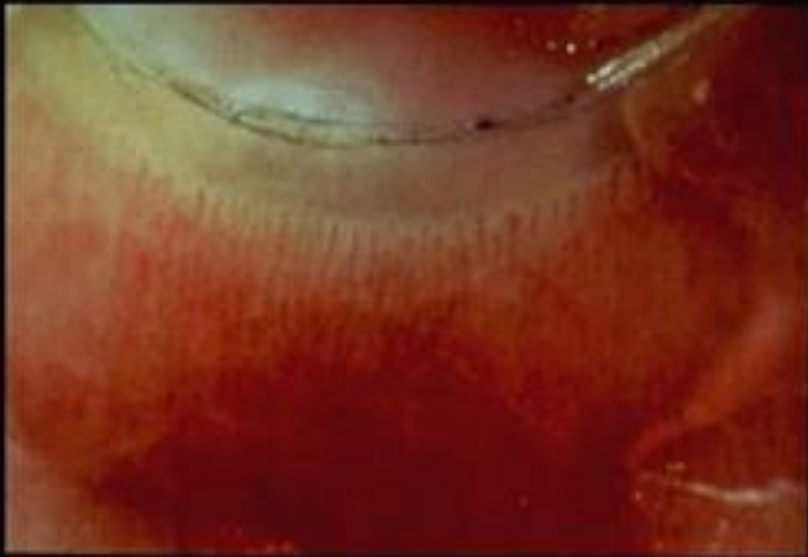






© ACR





Calcinosis

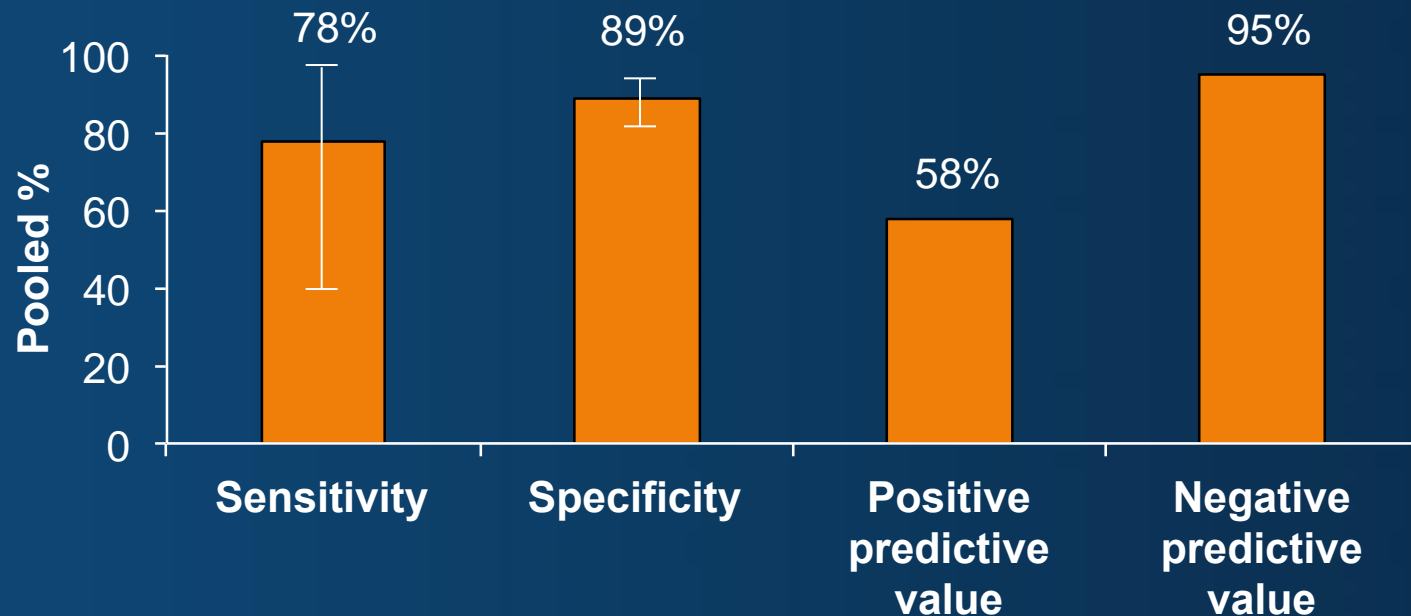
- Difficult
- No proven therapies
 - Heparin
 - Calcium channel blockers
 - Bisphosphonates
 - Sodium Thiosulfate (Calciphylaxis)
 - Extracorporeal shock-wave lithotripsy

Cancer Associated Myositis (CAM)

- Controversial
- Reports range from 10-25%
- If real, men over age 50 yrs at greatest risk
- Common CA: Breast, lung, ovary, uterus, GI, NHL
- 60% the myositis appears 1st, 30% neoplasm 1st, and 10% contemporaneously
- Avoid invasive, expensive searches for occult neoplasia
- Anti-p155 antibodies target TIF1 proteins
 - Predictive of CAM: Sensitivity 78%; Specificity 89%
- Tends to have rapid, severe onset, worse prognosis
- Dx: suspicion!

Cancer-associated dermatomyositis (DM) and anti-p155 autoantibodies

- Background: Anti-p155 autoantibody is directed against transcription intermediary factor 1 gamma (TIF-1 γ). TIF-1 proteins have positive and negative regulatory roles in carcinogenesis
- Meta-analysis of 6 studies (312 pts) assoc w/anti-p155 Ab w/ CA-DM



A DM pt anti-p155 positive has a OR= 27fold higher risk cancer-associated myositis

Clinical Assessment

- H&P
- Brooklyn HAQ “How you doin”?
- Observation (gait)
- Muscle testing – seated, rising
- Neurologic exam
- HAQ
- Muscle enzymes:
 - CPK, Aldolase, AST, ALT
- Autoantibodies

Diagnostic Testing

- Acute phase reactants unreliable
- Muscle Enzymes
 - CPK: elevated >65%; >10% MB fraction is possible
 - Muscle specific- Aldolase, Troponin, Carb. anhydrase III
 - AST > LDH > ALT
 - Beware of rising creatinine (ATN) and myoglobinuria
- Serologic Tests: ANA (+) 60%, Abs against t-RNA synthetases (anti-Jo1 Antibody)

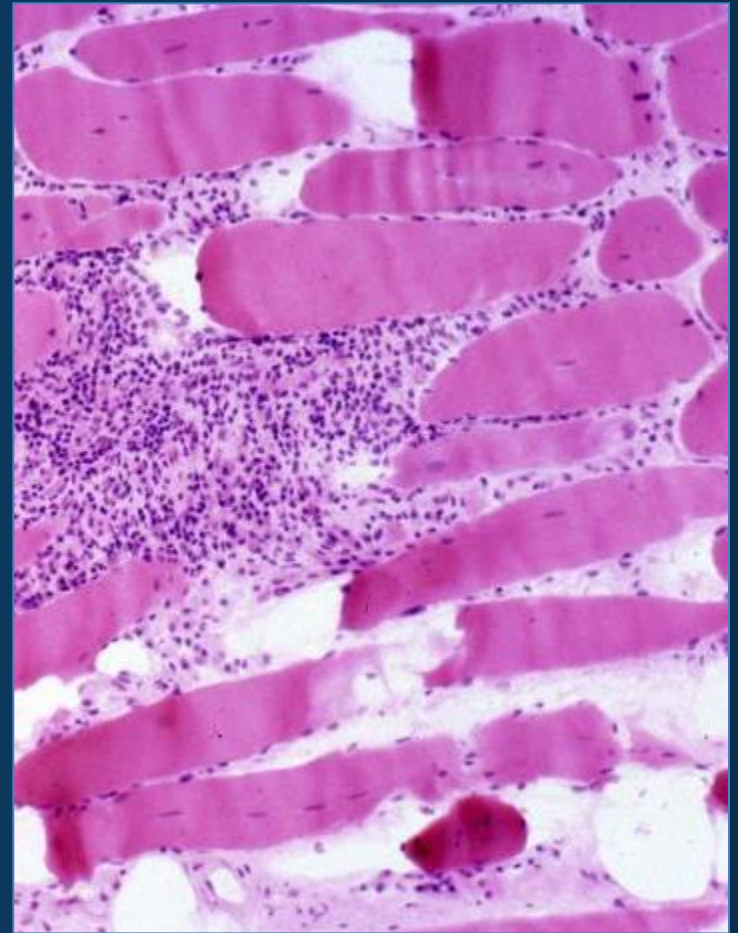
Diagnostic Testing

- Electromyogram: increased insertional activity, low amplitude, polyphasics, positive sharp waves
 - Beware of neuropathic changes
- Muscle Biopsy (an URGENT not elective procedure)
 - Call the neuropathologist! 85% Sensitive.
 - Biopsy involved muscle (MRI guided)
 - Avoid EMG/injection sites or sites of trauma
- Magnetic Resonance Imaging - detects incr. water signal, fibrous tissue, infiltration, calcification
- Investigational: Tc-99m Scans, PET Scans

Inflammatory Myositis

Biopsy Findings

- Inflammatory cells
- Edema and/or fibrosis
- Perifascicular atrophy
- Necrosis/ degeneration
- Centralization of nuclei
- Variation in muscle fiber size
- Rarely, calcification

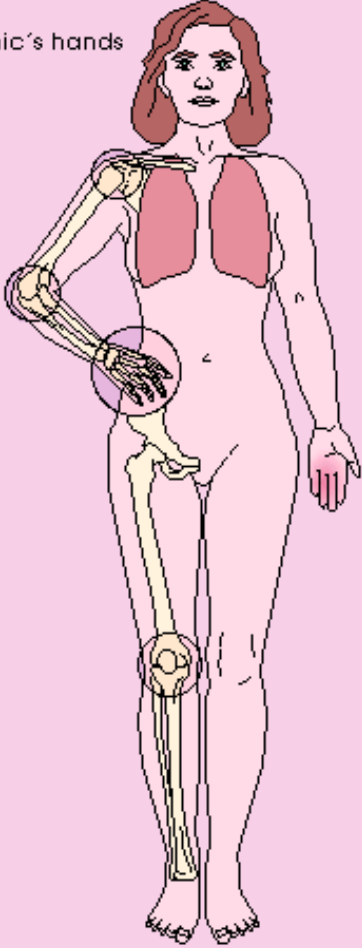
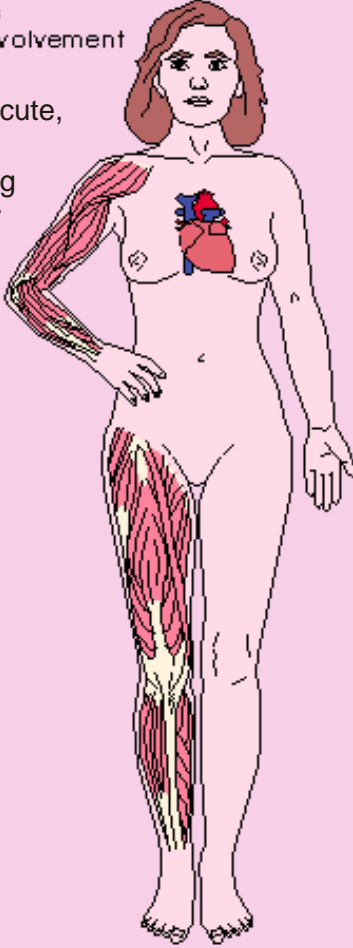
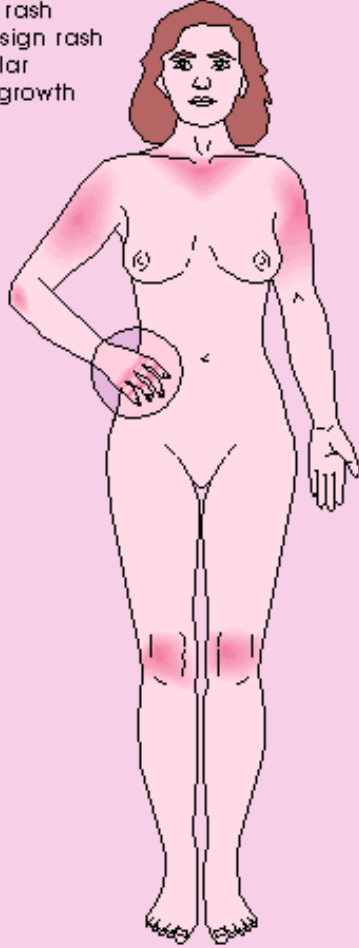


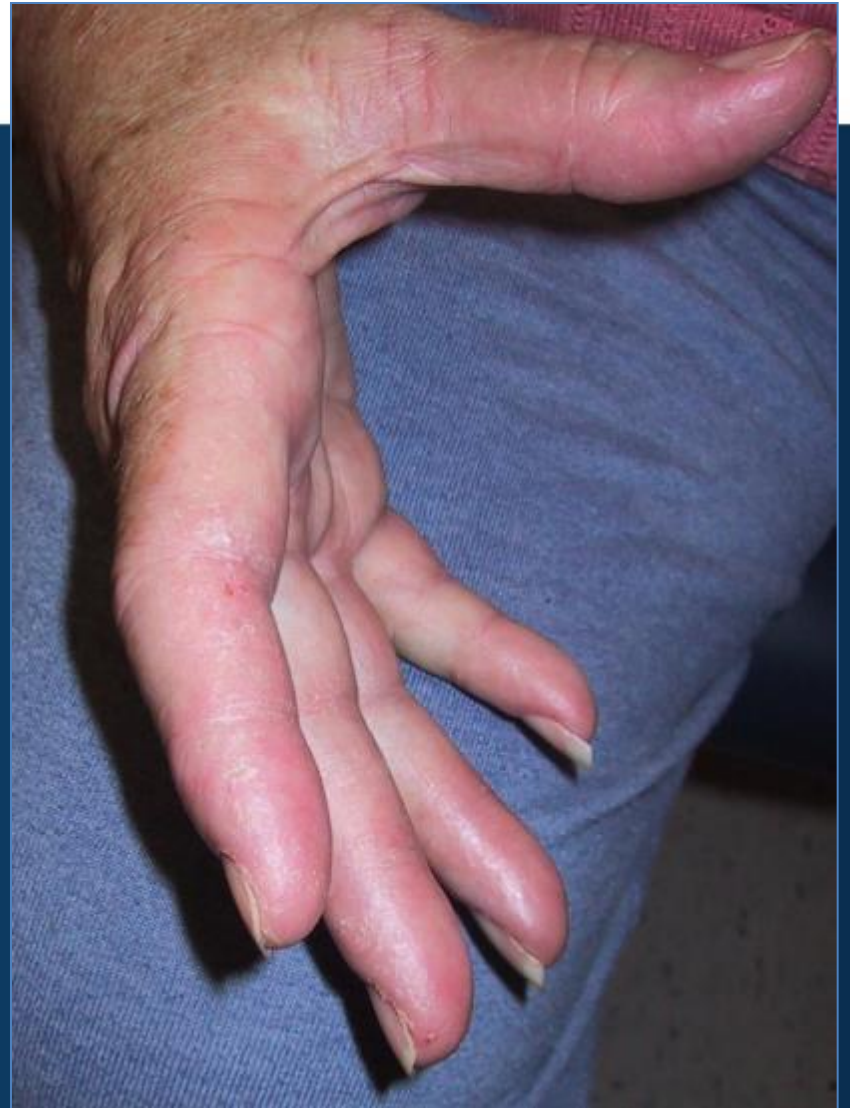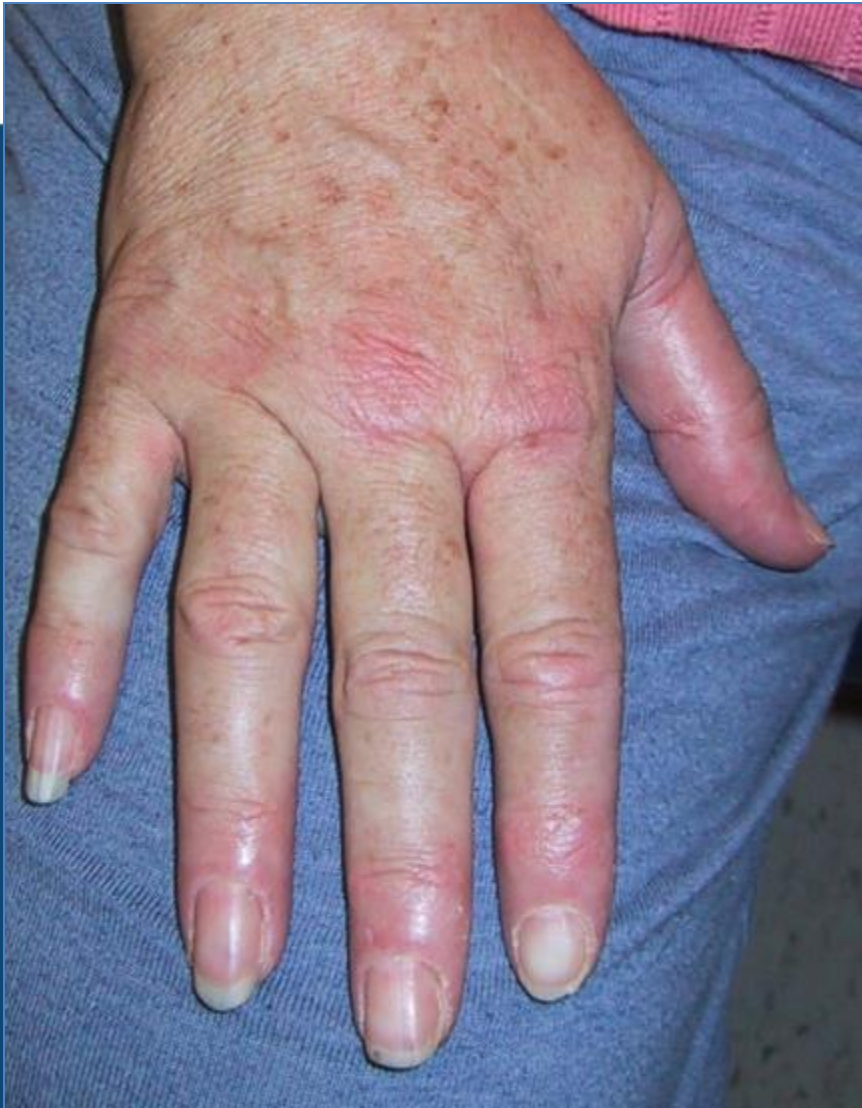ANTI-Aminoacyl-tRNA Synthetase Antibodies and their Associated Antigens in Polymyositis/Dermatomyositis

Antibody	Antigen	Polymyositis/ dermatomyositis Patients with antibody (%)
Anti-Jo-1	Histidyl-tRNA synthetase	20
Anti-PL-7	Threonyl-tRNA synthetase	<3
Anti-PL-12	Alanyl-tRNA synthetase	<3
Anti-OJ	Isoleucyl-tRNA synthetase	<3
Anti-EJ	Glycyl-tRNA synthetase	<3

Anti-synthetase syndrome: ILD, fever, arthritis,
Raynauds, Mechanics hands

Associations of Clinical Abnormalities with Myositis-Specific Autoantibodies

Antisynthetase	Anti-SRP	Anti-Mi-2
<ul style="list-style-type: none">• interstitial lung disease• arthritis• mechanic's hands• fever  <p>The diagram shows a female figure with a skeletal overlay. The lungs are highlighted in red, and the joints of the hands and knees are circled in purple, indicating arthritis and mechanic's hands. The figure is standing with one hand on her hip and the other pointing towards her chest.</p>	<ul style="list-style-type: none">• acute severe muscle weakness• cardiac involvement• myalgias• Severe, acute, resistant necrotizing myopathy  <p>The diagram shows a female figure with a muscle overlay. The heart is highlighted in red, and the muscles of the arms and legs are highlighted in red. The figure is standing with one hand on her hip and the other pointing towards her chest.</p>	<ul style="list-style-type: none">• classic dermatomyositis• V-sign rash• shawl-sign rash• cuticular overgrowth  <p>The diagram shows a female figure with skin involvement. The V-sign rash is highlighted in red on the upper chest, and the shawl-sign rash is highlighted in red on the shoulders and upper arms. The figure is standing with one hand on her hip and the other pointing towards her chest.</p>



Autoantibodies in PM/DM

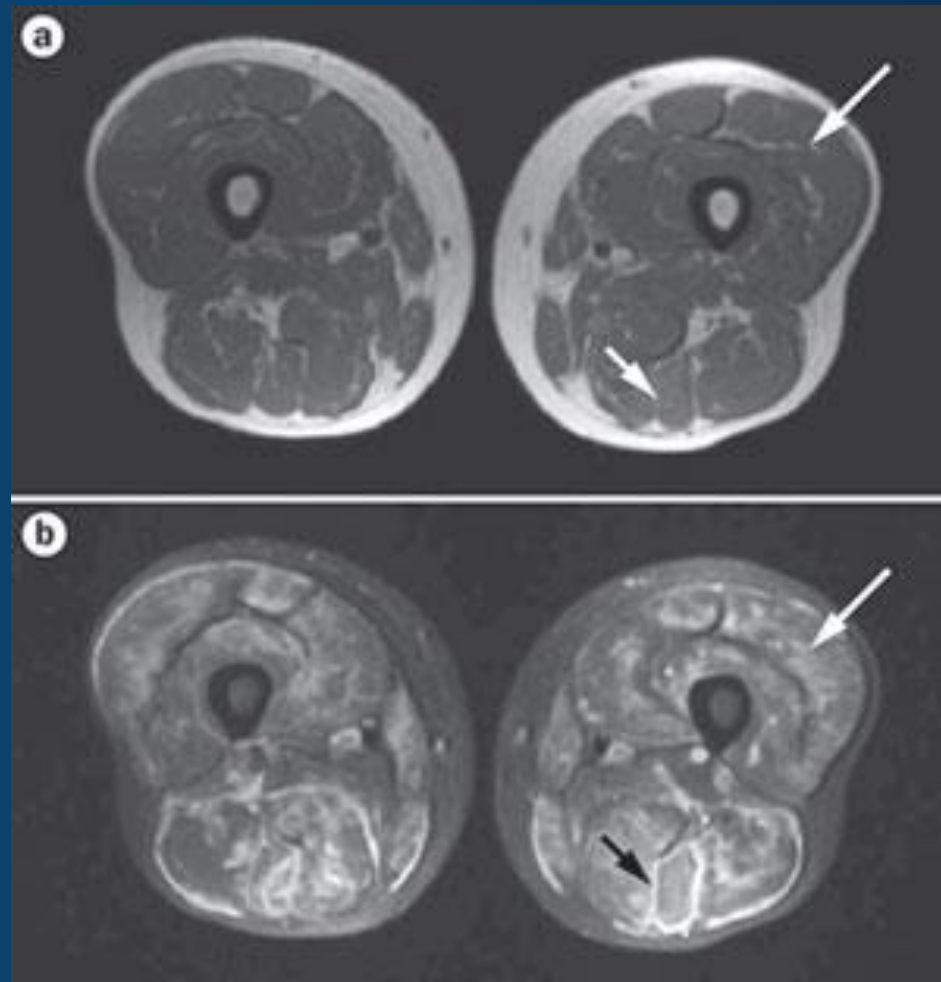
Ab	Freq (%)	Clinical Syndrome
ANA	50	Myositis
U1-RNP	15	SLE + myositis
Ku	<5	PSS + myositis overlap
Mi2	30	Dermatomyositis
PM1	15	PSS – PM overlap
Jo-1	25	Arthritis+ ILD+ arthritis
Ro52*	?	Severe myositis, Cancer risk
SS-B (La)	<5	SLE, Sjogrens, ILD, PM
PL-12,7, EJ, OJ, KS, Zo, Tyr	<5	ILD + PM or ILD > PM

* Coassociated w/ other anti-synthetase Abs

Anti-Synthetase Syndrome

- Proposed Criteria ASS
 1. +anti-tRNA synthetase serology
 2. one or more:
 - Myositis by Bohan/Peter criteria
 - ILD by ATS criteria
 - Arthritis
 - Unexplained fever
 - Raynauds
 - Mechanic' s hands

Figure 2 Thigh MRI from a Patient with Dermatomyositis



Pulmonary Involvement

- Interstitial lung disease (ILD)
- Respiratory muscle weakness, aspiration, infections, and drug-induced disease.
- ILD may precede myositis, results in increased rates of morbidity / mortality. NSIP is the most common

Study/Year	NSI Pa	IUP	COP	DAD	LIP	Unclassified
Fujisawa et al ⁸⁰ /2005, N = 10	7	3	0	0	0	0
Cottin et al ² /2003, N = 17	11	2	2	0	1	1
Tansey et al ⁸¹ /2004, N = 13	7	1	5	0	0	0
Shi et al ⁷⁷ /2008, N = 26	14	1	4	5	2	0
Fathi et al ¹³ /2004, N = 11	4	5	2	0	0	0
Won Huh et al ¹⁶ /2007, N = 9	4	4	0	1	0	0
Totals: N = 86	47	16	13	6	3	1

COP = cryptogenic organizing pneumonia; DAD = diffuse alveolar damage; LIP = lymphocytic interstitial pneumonia; NSIP = nonspecific interstitial pneumonia; UIP = usual interstitial pneumonia.

PM/DM Complications

PULMONARY

- Intercostal, diaphragm involvement
- Aspiration pneumonitis
- Infectious pneumonitis
- Drug induced pneumonitis
- Fibrosing alveolitis
- RARE:
 - Pulmonary vasculitis
 - Pulmonary neoplasia
 - Pulmonary hypertension

CARDIAC

- Elev. CPK-MB
- Mitral valve prolapse
- AV conduction disturbances
- Cardiomyopathy
- Myocarditis

Infections in Poly/Dermatomyositis

- 3 large retrospective studies
 - SIE 11.1 per 100 pt-yrs (28-38% of pts → SIE)
 - Opportunistic infxn in 11-18%; Aspiration pneumonia >20%
 - SIE ↓ survival to 68.3% at 1 year; Mortality rates 20-30%
 - ↑Risk:Age>45 (OR 5.3), Arthritis (2.6), ILD (7.2), AZA IVIG (6.1)

SIE	N	192 PM/DM pts 1999-2008
Pneumonia	30	Klebsiella (7), S aureus (6), P aeruginosa (4), H influenzae (4), Serratia (1), Acinetobacter (2), Stenotrophomonas (1), Prevotella (1),
Soft Tissue	13	S aureus (5), Klebsiella (2), Bacteroides (2), S pyogenes (1), Group D Strept (1), Enterococcus (1), Proteus (1), Peptostreptococcus (1)
UTI	9	E. coli (6), K pneumonia (2), Proteus mirabilis (1),
Bacteremia	8	Salmonella (6), E. coli (1), Streptococcus pneumonia (1)
Mycobacterial	7	M. Tuberculosis (6), Mycobacterium avium intracellulare (1)
Opportunistic	8	CMV, Varicella Zoster, Candida albicans,

Infections in Poly/Dermatomyositis

- Opportunistic infx in 18/156 pts (11.1%) PM/DM pts
 - 69% occurred in 1st year
 - OI: *Candida*, *Pneumocystis*, *Aspergillus*, *Geotrichum capitatum*, MAI, *M. xenopi*, *M. marinum*, *M. Tbc*, *Helicobacter heilmanii*, CMV, HSV.
 - Mortality rates 27.7%. Assoc. w/ higher dose steroids, lymphopenia, and lower serum total protein levels
- 104 Severe Infections in 279 PM/DM pts (37.3%)
 - 46/71 Pyogenic infections secondary to Aspiration Pneumonia
 - 33 Pyogenic infx: *Candida*, *Pneumocystis*, *Aspergillus*, *Myco-bacterium*, CMV, HSV, *H. Zoster*, HBV, HCV, JC virus, *Leishmania*, *Strongyloides*
 - Risk: Esophageal dysfunction, respiratory insufficiency, malignancy, lymphopenia

Inflammatory Myositis

Treatment

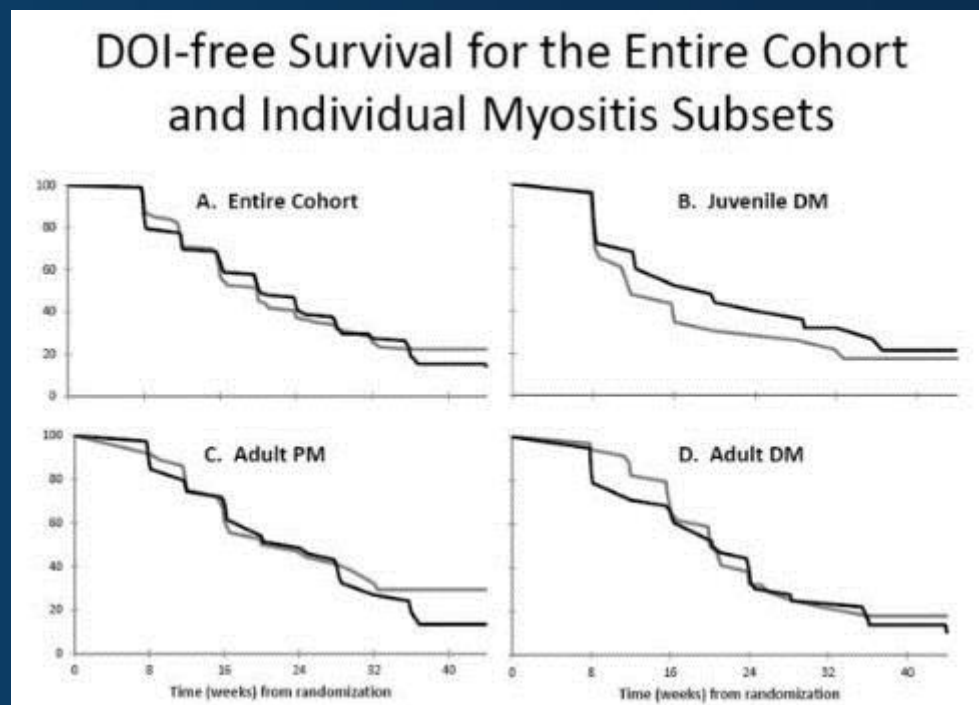
- Early Dx, physical therapy, respiratory support
- Corticosteroids : 80 mg/day (Ziffism)
 - 80% respond within 12 weeks
- Steroid resistant
 - Methotrexate
 - Azathioprine
 - Leflunomide, Mycophenolate, Tacrolimus
- IVIG, Cyclosporine, Chlorambucil, Sirolimus
- No response to apheresis, TNF inhibitors

Leflunomide Efficacy in IIM

- Lange U, et al. Anti-Jo-1 antibody positive polymyositis--successful therapy with leflunomide. *Autoimmunity*.2006;39:261-4.
- Sangle VS, et al. Leflunomide as a remission-maintaining therapy in difficult-to-treat dermatomyositis. *Ann Rheum Dis*. 2008;67:723.
- Boswell JS, et al. Leflunomide as adjuvant treatment of dermatomyositis. *J Am Acad Dermatol*. 2008;58:403-6.
- Gómez Rodríguez N, et al. Development of dermatomyositis in a woman with rheumatoid arthritis treated with leflunomide. *Ann Med Interna*. 2005 Jun;22(6):300-1

Rituximab in Dermato-/Polymyositis

- 200 pts DBRPCT: adults and Pediatric IIM
- All receive glucocorticoids \pm immunosuppressives
 - Early IV RTX
 - Late IV RTX
- No difference in response groups
- 83% improved
- Trial Design?



INFLAMMATORY MYOSITIS

Future Therapies

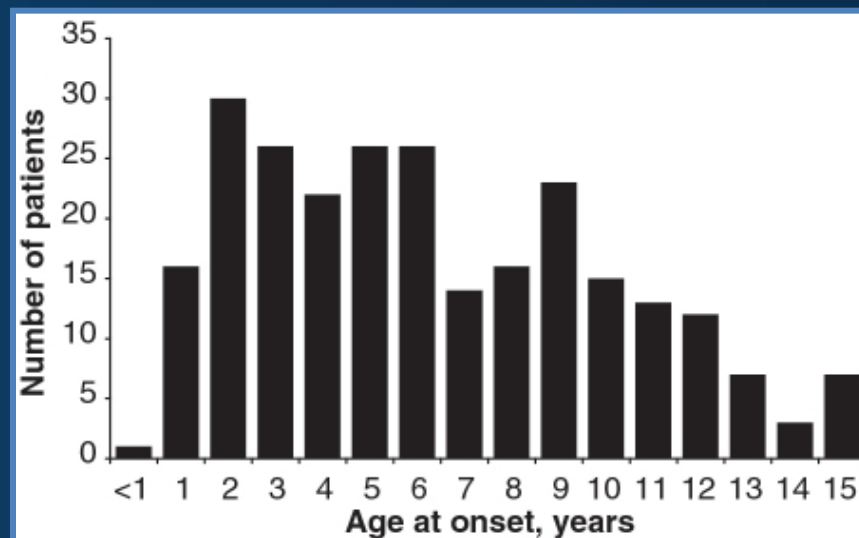
- α Interferon Abs
- Rituximab (anti-B cell mAbs)
 - Good Open-label results
 - DB-RCT in PM/DM/JDM 200 pts: failed for not meeting primary composite endpoint
- Anti-lymphotoxin mAbs (TNF β)
- Anti-Cytokine (IL6? IL-1?)
- Anti- Chemokine
- Autologous Stem Cell Transplantation

Refractory Patients w/ Myositis

- Is this the right diagnosis?
- Is this burnt out or active inflammatory disease?
- My Approach:
 - Get MRI
 - Rebiopsy or re-EMG
 - MTX + Leflunomide
 - Consider IVIG, Tacrolimus, Cyclosporine, Anakinra
 - Stem cell transplantation

Outcomes of Juvenile Dermatomyositis

- 53 pts w/ JDM
- 60% had disease damage
- F/U 13.9 yrs after onset
 - Calcinosis in 20%,
 - Lipodystrophy 13%
 - damage >2 org syst 24.5%
- 490 pts w/ JDM & Dz duration 7.7 years
 - Muscle weakness 41.2–52.8% (severe in 10%)
 - 69% Cumulative damage
 - calcinosis 24% and lipodystrophy 10%
 - Mortality rate was 3.1%.



Prognosis

- 10 yr survival > 90%
- Poor in pts. with delayed Dx, low CPK, early lung or cardiac findings, malignancy
- Neoplasia in 10% of adults
- PT for muscle atrophy, contractures, disability
- Kids: 50% remission, 35% chr active disease
- Adult < 20 yrs. do better than > 55 yrs.
- Adults: Mortality rates betw. 28-47% @ 7 yrs.
- Relapses & functional disability are common
- Death: due to malignancy, sepsis, pulm. or cardiac failure, and complications of therapy